

Twenty four hour imaging delay improves viability detection by Tl-201 myocardial perfusion scintigraphy

Atraso de imagem de 24 horas melhora a viabilidade de detecção por cintilografia de perfusão miocárdica Tl-201

Zehra Pınar Koç¹; Tansel Ansal Balcı¹; Necati Dağlı¹

DOI: 10.5935/1678-9741.20130081

RBCCV 44205-1503

Abstract

Objective: Since twenty-four-hour imaging by Tl-201 myocardial perfusion scintigraphy has been introduced as an effective additional procedure, the aim of this study was to compare this method's result with only rest redistribution procedure in the diagnosis of myocardial viability.

Methods: Thirty patients (Seven female, 23 male; mean: 59.8 ± 10.7, 55.8-63.8 years old) with diagnosis of coronary artery disease were involved in this study. All patients had anamnesis of previous myocardial infarction and/or total occlusion of any main artery in the coronary angiography. Myocardial perfusion scintigraphy with Tl-201 with rest four hour (early) redistribution and 24 hour delayed redistribution protocol were performed to all of the patients. The images were evaluated according to 17 segment basis by an experienced nuclear medicine physician and improvement of a segment by visual interpretation was considered as viable myocardial tissue.

Results: Viability was found at 52 segments in the early redistribution images and additional 18 segments in the 24 hour delayed redistribution images on segment basis in the evaluation of 510 segments of 30 patients. On per patient basis, among

the 26 patients who had viable tissue, 14 (54%) had additional improvement in 24 hour delayed images. Three (12%) patients had viable tissue in only 24 hour delayed images.

Conclusion: Delayed imaging in Tl-201 MPS is a necessary application for the evaluation of viable tissue according to considerable number of patients with additional improvement in 24 hour images in our study, which is restricted to the patients with myocardial infarct.

Descriptors: Vascular diseases. Coronary artery bypass. Coronary artery disease.

Resumo

Objetivo: Dado que a cintilografia Tl -201 24 horas de imagens por perfusão miocárdica foi introduzida como um procedimento adicional efetivo, assim, o objetivo deste estudo foi comparar os resultados deste método com o procedimento único de redistribuição no diagnóstico de viabilidade miocárdica.

Métodos: Trinta pacientes (Sete mulheres, 23 homens, média: 59,8 ± 10,7, 55,8-63,8 anos) com diagnóstico de doença arte-

¹Firat University Hospital, Elazig, Turkey.

Work carried out at Firat University Hospital, Elazig, Turkey.

No financial support.

Correspondence address:

Zehra Pınar Koç

University Hospital Nuclear Medicine Dpt. – B3 –

Elazig, Turkey

Zip code: 23119

E-mail: zehrapinarkoc@gmail.com

Article received on March 11th, 2013

Article accepted on August 20th, 2013

Abbreviations, acronyms & symbols	
ATP	Adenosine triphosphate
CABG	Coronary artery bypass graft surgery
CAD	Coronary artery disease
C-MRI	Cardiac applications of magnetic resonance imaging
MPS	Myocardial perfusion scintigraphy
MR	Magnetic resonance
SPECT	Single photon emission computed tomography

rial coronariana foram avaliados neste estudo. Todos os pacientes tinham anamnese de infarto do miocárdio e/ou oclusão total de uma artéria principal na cinecoronariografia. Cintilografia de perfusão miocárdica com protocolo de Tl-201 em repouso, redistribuição quatro horas (início) e redistribuição tardia 24 horas foi realizada em todos os pacientes. As imagens foram avaliadas de acordo com a base de 17 segmentos por um médico com experiência em medicina nuclear e melhoria de um

INTRODUCTION

Myocardial infarction is a critical event and the most common cause of death all over the world. After myocardial infarction, another critical course begins which includes the decision of both presence and extent of the viable myocardial tissue. Since myocardial tissue sometimes preserves its viability by some adaptation methods during infarct, it is possible to observe viable tissue in patients who experienced myocardial infarction. The ‘hibernating’ myocardial tissue is a tissue with impaired flow and function, but with preserved viability.

This state of the myocardial tissue can be seen especially by means of radionuclide imaging methods like Tl-201 and F-18 FDG PET/CT. Recently, new methods have been introduced to the field of imaging of the myocardial viability, such as cardiac applications of magnetic resonance imaging (C-MRI) or stress echocardiography [1]. However diagnostic power of the viability assessment by Tl-201 is underestimated because most of the recent comparative studies with Tl-201 imaging involve rest redistribution protocol [2]. The aim of this study was to investigate diagnostic importance of 24 hour delayed Tl-201 imaging in our series.

METHODS

Patients

Thirty patients (seven female, 23 male; mean: 59.8±10.7, 55.8-63.8 years old) with diagnosis of coronary artery disease were included in this study. Diagnosis of myocardial infarct was based on anamnesis, electrocardiography results and/or coronary angiography results showing 100% narrowing of any main coronary artery. Sixteen patients underwent additional coronary angiography. All patients had documented myocar-

segmento por interpretação visual foi considerado como tecido miocárdico viável.

Resultados: A viabilidade foi encontrada em 52 segmentos de redistribuição das imagens iniciais e 18 segmentos adicionais nas imagens de redistribuição tardias de 24 horas baseadas em segmento, na avaliação de 510 segmentos de 30 pacientes. Em termos de pacientes, entre os 26 pacientes que tinham tecido viável, 14 (54%) apresentaram melhora adicional em imagens tardias de 24 horas. Três (12%) pacientes tiveram tecido viável apenas em imagens tardias de 24 horas.

Conclusão: A imagem tardia em TL- 201 MPS é uma aplicação necessária para a avaliação do tecido viável de acordo com o número considerável de pacientes com melhora adicional em imagens de 24 horas em nosso estudo, o qual é restrito aos pacientes com infarto do miocárdio.

Descritores: Doenças vasculares. Ponte de artéria coronária. Doença da artéria coronariana.

dial infarction. Additionally, all the patients had segmental or global wall motion abnormalities and left ventricular impairment (mean ejection fraction: 30.9±8.9) according to the echocardiography results. Patient characteristics are summarized in the Table 1.

All the patients’ informed consent forms were obtained prior to the study and after explaining the procedure and the research. Ethics committee approval was not deemed necessary since the study was performed retrospectively.

Table 1. Patient characteristics.

	Nº of patients
Age	56-64 years
Gender	7 female/23 male
Angina	19
Smoking	16
Diabetes mellitus	8
Hypertension	14
Family history	5
Hyperlipidemia	9
Previous CABG	3

CABG: Coronary artery bypass graft surgery

Myocardial perfusion scintigraphy

Tl-201 myocardial perfusion scintigraphy (MPS) with rest redistribution and delayed redistribution protocol were performed in all patients with the same imaging and acquisition protocols (same timing, filter, gated acquisition, reconstruction parameters (filtered back projection), attenuation and scatter correction). After a fasting period of at least four hours approximately 2 mCi (74 Mbq) Tl-201 (the dose was limited to 2 mCi in case reinjection was required, which did not happen in this approach) was injected via venous line into

the patients. Rest images were obtained at five-ten minutes, early redistribution images at 3-4 hours and late redistribution images at 24 hours after the injection.

Single photon emission computed tomography (SPECT) imaging was performed by a dual-head gamma camera equipped with low energy all purpose collimator (GE, Infinia). The images were acquired over a 180° arc in 64 projections, each lasting 30 seconds (in case of insufficient quality of images by visual analysis, the imaging time was increased to 40 sec/per frame), in a 64x64 matrix and gated protocol. The butterworth filter with cutoff frequency of 0.5 and order of 10 was applied for the reconstruction of the images.

Image interpretation

The images were evaluated in short axis, vertical and horizontal long axis slices, and in bull’s eye imaging. This was done according to 17 segment basis by two independent experienced nuclear medicine physicians and improvement of any segment by visual interpretation (greater than 50% uptake increase) was considered as viable myocardial tissue. The analysis of scores (0-4 scores and % scores) was performed by the same physicians.

Statistical analysis

The comparison of the scores was done by paired samples T test and $P<0.05$ was considered statistically significant. SPSS 15.0 was used for the analysis.

RESULTS

In the evaluation of 510 segments of 30 patients, 52 segments in early redistribution images and other 18 segments in delayed redistribution images were considered viable on a segment basis. In order to consider the improvement between the

rest-redistribution and delayed redistribution images, a significant difference between % scores of the segments ($P<0.05$) or improvement of 0-4 scores by at least one degree was accepted as a threshold. On per patient basis, among the 26 patients who had viable tissue, 14 (54%) had additional improvement on delayed images. Three (12%) patients had viable tissue only on delayed imaging (Figure 1). Additionally all the patients had global or segmental wall motion abnormalities and mean ejection fraction value obtained from rest redistribution images was 30.9 ± 8.9 according to Gated acquisition.

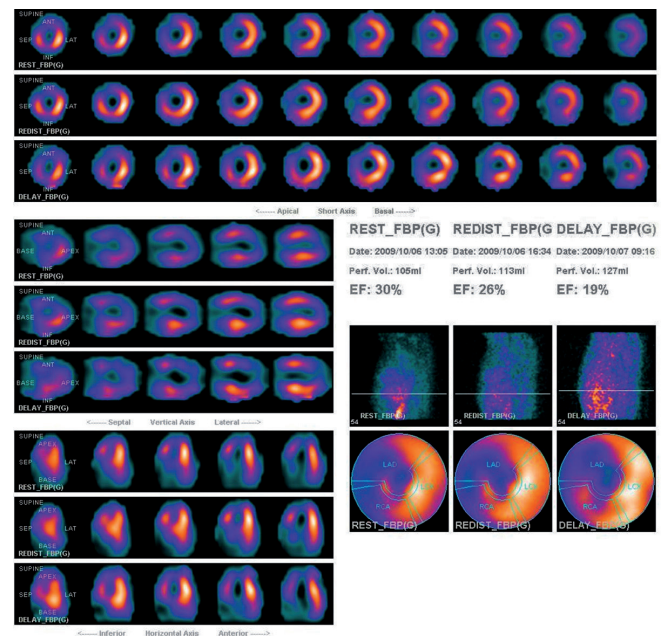


Fig. 1 - Short axis, vertical axis, horizontal axis, and bulls eye Tl-201 MPS images of a patient who has viable tissue only in 24 hour images in septum and anteroseptal wall

Table 2. Myocardial perfusion scintigraphy results of patients who have angiography results.

Angiography	Redistribution	Delayed Imaging
1 LAD 100%	-	Inferior, septum
2 LAD 80%, Cx 90%	Septum	Anterior mid
3 LAD-LIMA 100%	Anteroseptal, inferior mid apical	Lateral basal
4 LAD 95%, Cx 100%	Anterior mid	Anterior apical
5 LAD 100%	-	Apex
6 LAD 100%, Cx 50%, RCA 95%	Anterior mid	Septum
7 LAD 95%	Septum	Anteroseptal mid
8 LAD 100%, RCA 90%	Apex	-
9 LAD 98%, Cx90%, RCA 95%	-	-
10 LAD 100%	-	Inferior apical
11 LAD 70%, Cx 100%, RCA 70%	Septum	-
12 RCA 80%	Inferior	Inferolateral
13 Cx %90	Inferior	Septum, anteroseptal mid
14 LAD 100%, Cx 95%, RCA 100%	Septum, anteroseptal, inferoseptal	-
15 LAD 100%, Cx 40%, RCA 100%	Anterior mid apical	Apex
16 LAD 100%, Cx 70%, RCA 100%	Anteroseptal mid	Anteroseptal basal

The improved segments at rest redistribution and delayed imaging of patients who underwent angiography are summarized in Table 2.

Unfortunately, all the patients were out of follow up after the establishment of the viability. There was no information regarding further management of the patients, whether or not they underwent coronary artery bypass graft surgery (CABG), and what their results were.

DISCUSSION

Since mortality associated with the heart failure is significantly high, it is important to perform revascularization in patients who might benefit from this procedure. According to a meta-analysis study, revascularization procedures have provided improvements in 79.6% of patients with viable tissue [3]. Viability assessment have gained importance ever since risk factors associated with CABG operations, especially in elderly patients, have become known [4,5]. Viability assessment by means of radionuclide imaging methods is generally effective because these methods provide functional assessment of the myocardial tissue. Tl-201 is a potassium analog and enters myocytes via an active transport mechanism involving the Na⁺/K⁺ adenosine triphosphate (ATP) transport system. When Tl-201 enters intracellular space, it goes back to the systemic circulation through diffusion [6].

This kinetic redistribution, which is specific to this agent, allows viability assessment by Tl-201 imaging. The tracer is taken by hibernating myocardium and it can be seen at three hours after injection of radiopharmaceutical. Since Pohost et al. [7] first introduced Tl-201 as a viability agent further studies have shown that 24 hour imaging provides important prognostic data [8,9]. Perrone-Filardi et al. [10] observed improvement in approximately 20% of segments in late images, especially in mild to moderately persistent defects. Rest redistribution imaging at three hours is not a sufficient approach as documented in a series which showed 75% of the viability were reported as scars, according to rest-redistribution only Tl-201 imaging [11].

Dilsizian et al. [12] were the first to report the 'reinjection technique', which includes a lower dose (1 mCi/37 MBq) Tl-201 injection at three hours and then reimaging. However, 24 hour imaging with Tl-201 still preserves its diagnostic significance as documented in a recent study [13]. In this comparative study with echocardiography follow up, researchers observed 20% more segments with viability in the 24 hour images that had not improved in rest redistribution imaging. We found 26% (18 out of 70 viable segments) additional segments with improvement in the 24 hour images. Although previous researchers performed 24 hour imaging with a higher Tl-201 dose (3-4 mCi/111-148 mBq) we did not increase the dose.

The justification for increasing the dose of radiopharmaceutical is the poor image quality of Tl-201 especially in de-

creased dose of 24 hour images. However the image quality of our study at 24 hours was in fact comparable to the early redistribution images even close to Tc-99m MIBI images, according to visual interpretation and target non target ratio (2.03; 2.16 and 3.03, respectively). We just preferred to increase the time frame (40 sec versus 30 sec per frame), if necessary. The patient based analysis of the viability assessment in our study revealed that an important percentage of patients (54%) had additional viable tissue in 24 hour images. Since the patients who were included in this study all had fixed defects on rest Tl-201 imaging, this finding is of great importance. The most important result of this study is patients who had improvement only in 24 hour imaging (three patients, 12%), which was not observed in any previous study. However, due to the small sample size the ratio of these patients should be evaluated in a larger study population. In future studies this percentage might increase.

The cardiac Tc-99m labeled tracers have superior image quality compared to Tl-201. That is why there are new approaches with Tc-99m compounds employed in the viability assessments. Maurea et al. [14] have shown that administering nitrate during Tc-99m MIBI imaging might demonstrate viable tissue in patients with chronic heart failure. A recent comparative study using this method and the Tl-201 reinjection approach has demonstrated comparable results and good agreement between the two methods [15].

Another recent approach with Tc-99m compounds has included Tc-99m labeled HL91, which is introduced as an alternative application for the viability assessment. Viability was defined as reduced Tc-99m MIBI uptake and increased Tc-99m HL91 uptake; a 'mismatch' pattern, especially in the three hour images, which showed high diagnostic accuracy [16].

The most important advance in the field of viability imaging was F-18 FDG PET/CT. Viability assessment by means of F-18 FDG PET has shown significant superiority over 24 hour Tl-201 imaging [17]. F-18 FDG PET has been considered as the gold standard imaging method for detection of myocardial viability [18]. Additionally, according to previous studies, F-18 FDG PET has been able to provide prognostic information [3,19].

Stress echocardiography is another modality which shows viable tissue in the myocardium. According to a meta-analysis sensitivity, specificity, and positive and negative predictive values of dobutamin stress echocardiography were found to be 81%, 80%, 77%, and 85%, respectively [20]. The same researchers have mentioned that radionuclide methods have higher sensitivity and stress echocardiography has higher specificity.

Cardiac magnetic resonance (MR) imaging for assessment of the myocardial viability is a new method which can clearly identify cardiac tissue in all the myocardial layers with superior spatial resolution compared to the radionuclide

methods. An analysis of viability assessment by cardiac MR has concluded that MR is an excellent tool to demonstrate viability [21]. A comparative study with cardiac MR and Tl-201 imaging has documented that MR has higher specificity, negative predictive value and overall accuracy; however, in that study the Tl-201 imaging was performed in a rest redistribution manner [2]. Cardiac MR has had comparable diagnostic accuracy with PET according to a previous study [22].

One of the important characteristics of our study is the homogeneity of our study population, which consists only of patients with documented myocardial infarction. In other studies about viability assessment there have been patient populations with angiographically significant coronary artery disease (CAD), or patients with left ventricular impairment with myocardial infarction in some (50%) of the patients [23,24]. In those studies, significant percentages of the segments were already nonviable (144/398 and 56/240, respectively). However, the primary pathology of our patients was CAD with known myocardial infarct tissues thus our study includes subjects with periinfarct viable tissue.

Another study about viability assessment by both rest redistribution Tl-201 and contractile reserve assessment by low-dose dobutamine protocol included 41 patients, 39 of whom had documented myocardial infarction, and found the protocol easy and feasible [25]. Although their analysis did not include additional late Tl-201 imaging, their study group was similar to ours and a smaller percentage of the segments in their analysis was nonviable (33/890), as in our study. This specially enabled our study to evaluate more segments regarding viability.

Limitations of this study were its retrospective structure and lack of all the patients' angiography or follow up results. Quantification of the data also couldn't be performed because of a technical problem associated with our analysis program.

CONCLUSION

According to our results the 24 hour Tl-201 imaging is a necessary application for the identification of viable myocardial tissue. Considering the large number of patients who benefit from this additive method, this study can encourage future comparative studies with 24 hour imaging protocol and new diagnostic applications in this area.

There is no conflict of interest.

Author's roles & responsibilities	
ZPK	Corresponding, first author
TAB	Second author
ND	Third author

REFERENCES

1. Arrighi JA, Dilsizian V. Multimodality imaging for assessment of myocardial viability: nuclear, echocardiography, MR, and CT. *Curr Cardiol Rep.* 2012;14(2):234-43.
2. Regenfus M, Schlundt C, von Erffa J, Schmidt M, Reulbach U, Kuwert T, et al. Head-to-head comparison of contrast-enhanced cardiovascular magnetic resonance and 201Thallium single photon emission computed tomography for prediction of reversible left ventricular dysfunction in chronic ischaemic heart disease. *Int J Cardiovasc Imaging.* 2012;28(6):1427-34.
3. Aikawa P, Cintra AR, Leite CA, Marques RH, Silva CT, Afonso MS, et al. Impact of coronary artery bypass grafting in elderly patients. *Rev Bras Cir Cardiovasc.* 2013;28(1):22-8.
4. Sá MP, Nogueira JR, Ferraz PE, Figueiredo OJ, Cavalcante WC, Cavalcante TC, et al. Risk factors for low cardiac output syndrome after coronary artery bypass grafting surgery. *Rev Bras Cir Cardiovasc.* 2012;27(2):217-23.
5. Allman KC, Shaw LJ, Hachamovitch R, Udelson JE. Myocardial viability testing and impact of revascularization on prognosis in patients with coronary artery disease and left ventricular dysfunction: a meta-analysis. *J Am Coll Cardiol.* 2002;39(7):1151-8.
6. Demirkol MO. Myocardial viability testing in patients with severe left ventricular dysfunction by SPECT and PET. *Anadolu Kardiyol Derg.* 2008;8(Suppl 2):60-70.
7. Pohost GM, Zir LM, Moore RH, McKusick KA, Guiney TE, Beller GA. Differentiation of transiently ischemic from infarcted myocardium by serial imaging after a single dose of thallium-201. *Circulation.* 1977;55(2):294-302.
8. Gutman J, Berman DS, Freeman M, Rozanski A, Maddahi J, Waxman A, et al. Time to completed redistribution of thallium-201 in exercise myocardial scintigraphy: relationship to the degree of coronary artery stenosis. *Am Heart J.* 1983;106(5 Pt 1):989-95.
9. Kiat H, Berman DS, Maddahi J, De Yang L, Van Train K, Rozanski A, et al. Late reversibility of tomographic myocardial thallium-201 defects: an accurate marker of myocardial viability. *J Am Coll Cardiol.* 1988;12(6):1456-63.
10. Perrone-Filardi P, Pace L, Prastaro M, Squame F, Betocchi S, Soricelli A, et al. Assessment of myocardial viability in patients with chronic coronary artery disease. Rest-4-hour-24-hour 201Tl tomography versus dobutamine echocardiography. *Circulation.* 1996;94(11):2712-9.
11. Liu P, Kiess MC, Okada RD, Block PC, Strauss HW, Pohost GM, et al. The persistent defect on exercise thallium imaging and its fate after myocardial revascularization: does it represent scar or ischemia? *Am Heart J.* 1985;110(5):996-1001.

12. Dilsizian V, Rocco TP, Freedman NM, Leon MB, Bonow RO. Enhanced detection of ischemic but viable myocardium by the reinjection of thallium after stress-redistribution imaging. *N Engl J Med.* 1990;323(3):141-6.
13. He YM, Yang XJ, Wu YW, Zhang B. Twenty-four-hour thallium-201 imaging enhances the detection of myocardial ischemia and viability after myocardial infarction: a comparison study with echocardiography follow-up. *Clin Nucl Med.* 2009;34(2):65-9.
14. Maurea S, Cuocolo A, Soricelli A, Castelli L, Nappi A, Squame F, et al. Enhanced detection of viable myocardium by technetium-99m-MIBI imaging after nitrate administration in chronic coronary artery disease. *J Nucl Med.* 1995;36(11):1945-52.
15. Günel SE, Akgun A. Comparison of exercise-rest-reinjection Tl-201 imaging and rest sublingual isosorbide dinitrate Tc-99m MIBI imaging for the assessment of myocardial viability. *Ann Nucl Med.* 2009;23(5):451-7.
16. Liu M, Ma Z, Guo X, Zhu J, Su J. Technetium-99m-labelled HL91 and technetium-99m-labelled MIBI SPECT imaging for the detection of ischaemic viable myocardium: a preliminary study. *Clin Physiol Funct Imaging.* 2012;32(1):25-32.
17. Brunken RC, Mody FV, Hawkins RA, Nienaber C, Phelps ME, Schelbert HR. Positron emission tomography detects metabolic viability in myocardium with persistent 24-hour single-photon emission computed tomography 201Tl defects. *Circulation.* 1992;86(5):1357-69.
18. Ammirati E, Rimoldi OE, Camici PG. Is there evidence supporting coronary revascularization in patients with left ventricular systolic dysfunction? *Circ J.* 2011;75(1):3-10.
19. Rohatgi R, Epstein S, Henriquez J, Ababneh AA, Hickey KT, Pinsky D, et al. Utility of positron emission tomography in predicting cardiac events and survival in patients with coronary artery disease and severe left ventricular dysfunction. *Am J Cardiol.* 2001;87(9):1096-9.
20. Bax JJ, Poldermans D, Elhendy A, Boersma E, Rahimtoola SH. Sensitivity, specificity, and predictive accuracy of various noninvasive techniques for detecting hibernating myocardium. *Curr Probl Cardiol.* 2001;26(2):147-86.
21. Child NM, Das R. Is cardiac magnetic resonance imaging assessment of myocardial viability useful for predicting which patients with impaired ventricles might benefit from revascularization? *Interact Cardiovasc Thorac Surg.* 2012;14(4):395-8.
22. Knuesel PR, Nanz D, Wyss C, Buechi M, Kaufmann PA, von Schulthess GK, et al. Characterization of dysfunctional myocardium by positron emission tomography and magnetic resonance: relation to functional outcome after revascularization. *Circulation.* 2003;108(9):1095-100.
23. Wu YW, Huang PJ, Lee CM, Ho YL, Lin LC, Wang TD, et al. Assessment of myocardial viability using F-18 fluorodeoxyglucose/Tc-99m sestamibi dual-isotope simultaneous acquisition SPECT: comparison with Tl-201 stress-reinjection SPECT. *J Nucl Cardiol.* 2005;12(4):451-9.
24. Gutberlet M, Fröhlich M, Mehl S, Amthauer H, Hausmann H, Meyer R, et al. Myocardial viability assessment in patients with highly impaired left ventricular function: comparison of delayed enhancement, dobutamine stress MRI, end-diastolic wall thickness, and Tl201-SPECT with functional recovery after revascularization. *Eur Radiol.* 2005;15(5):872-80.
25. Heiba SI, Yee G, Abdel-Dayem HM, Youssef I, Coppola J. Combined rest redistribution thallium-201 SPECT and low-dose dobutamine contractility assessment in a simple and practical new viability protocol. *Ann Nucl Med.* 2009;23(2):197-203.